

# Skin Therapy Letter<sup>®</sup>

May 2017

Clinical Evidence. Practical Advice

Editor-in-Chief: Dr. Charles Lynde

## Dr. Charles Lynde, MD, FRCPC EDITOR-IN-CHIEF

Dr. Charles Lynde is an Assistant Professor in the Department of Medicine at the University of Toronto and holds a clinical teaching position at the University Health



Network. He is the Medical Director of Lynde Dermatology and Lynderm Research. Dr. Lynde is a member of the Canadian Dermatology Association (CDA), the American Academy of Dermatology (AAD), the European Academy of Dermatology and Venereology (EADV), the Toronto Dermatology Association as well as the Ontario Medical Association (OMA). His research interests include acne, psoriasis, and psoriatic arthritis, and has authored and co-authored more than 150 peer reviewed articles. Dr. Lynde has been the principal investigator in more than 160 clinical trials in dermatology. He is also the Editor of the CDA Bulletin and sits on the editorial boards of several journals and extensively consults and is on the advisory boards of many pharmaceutical companies.

## Dr. Colleen Lawlor, MD, CCFP FAMILY PRACTICE ADVISOR

Dr. Colleen Lawlor has chosen to build her family practice at Continuum Medical Care located in West Vancouver, BC. Dr. Lawlor has a BA in Psychology, an MSC in Nursing, and her MD, CCFP. She received her medical training at the University of Texas in San Antonio.



An archive of past issues  
is available at our website:  
[www.SkinTherapyLetter.com](http://www.SkinTherapyLetter.com)

## Toenail Onychomycosis – A Canadian Approach with a New Transungual Treatment – a Podiatrist Perspective

Alan D Boroditsky DPM<sup>1</sup> and Anneke Andriessen PHD<sup>2</sup>

<sup>1</sup>Vancouver General Hospital, Department of Podiatry, Vancouver, BC, Canada

<sup>2</sup>Malden and UMC St Radboud Nijmegen, The Netherlands

### Introduction

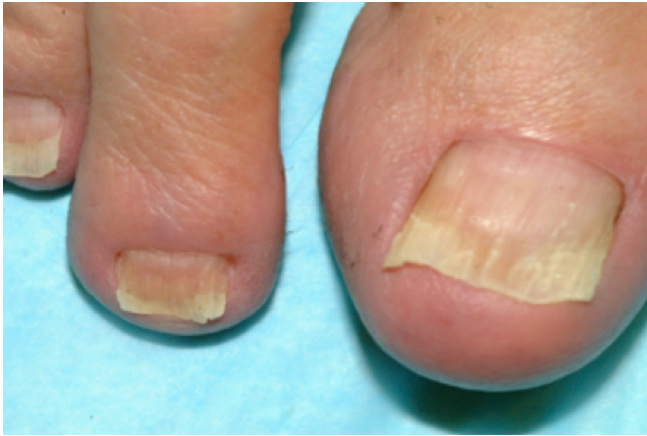Onychomycosis in diabetic patients increases the risk for other foot disorders and limb amputation and is included in diabetic foot ulcer guidelines as one of the risk factors for serious complications that should be screened for. Even though foot examination in diabetes patients is common practice, onychomycosis either goes unnoticed or is left untreated and remains unresolved. Early treatment and intervention including diabetic foot care and education is advisable owing to the progressive nature of fungal infections and the high-risk diabetic foot. Treatment with transungual efinaconazole 10% solution is an effective and safe option for many of these patients. A recently published clinical pathway for toe onychomycosis<sup>1</sup> is used as the basis for the management strategy presented here, and follows a pathway reflective of the therapeutic options available in Canada.

### Background

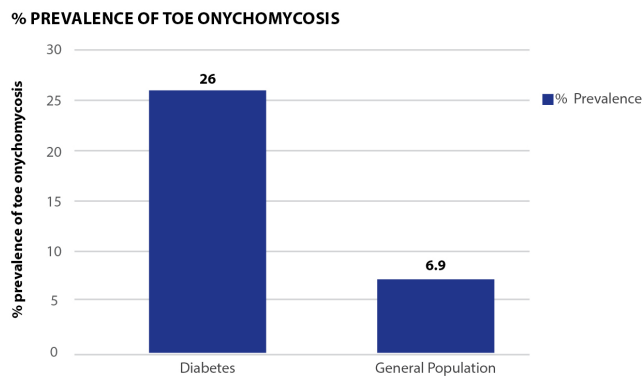
- Onychomycosis accounts for about half of all nail abnormalities and comprises a third of fungal skin infections.<sup>2</sup>
- The prevalence of onychomycosis becomes more common as people age and conditions such as diabetes, peripheral vascular disease, psoriasis and immunosuppression (HIV infection or immunosuppressive therapy) increase in our populations.
- Fungal nail disease can coexist with other nail disorders.<sup>2,3,6</sup>
- The prevalence of onychomycosis in patients with diabetes has been reported to be 26%.<sup>3-5</sup>
- Diabetics appear almost three times as likely to have onychomycosis as non-diabetic individuals.<sup>3-5</sup>
- Although there are no studies addressing the relationship between onychomycosis and diabetic foot ulcers, it is possible that one could predispose to the other.<sup>4</sup>
- Other factors enhancing the risk for onychomycosis are smoking; avid sports participation; the use of commercial swimming pools; wearing occlusive, tight footwear; use of common, hot, humid climates; and frequent travel to endemic areas.<sup>2</sup>
- This common nail infection often results in nail plate damage, deformity and toenail dystrophy that can interfere with walking.<sup>2</sup>
- It is also associated with detrimental psychosocial effects.<sup>7</sup>

### Toe Onychomycosis

- Onychomycosis is most frequently caused by dermatophytes (approximately 90% of toenail infections) and non-dermatophyte molds (approximately 6%) that mainly affect toenails (Figure 1).<sup>8,9</sup>
- Onychomycosis may present with four patterns of involvement.<sup>1</sup> Most common is a distal subungual pattern, where proximal subungual presentation is rare and often indicates immunodeficiency.<sup>1</sup> Yeast infections may present as a superficial white pattern and can be treated topically.<sup>1</sup> In advanced disease the whole nail plate may be involved, making the condition less responsive to therapy.<sup>1</sup>
- Onychomycosis is a serious condition in people with diabetes and increases their risk for other foot disorders and limb amputation (Figure 2).<sup>11,12,15,16,20</sup>
- Onychomycosis will often result in thickened and dystrophic nails that are difficult to manage for many patients because often they can't reach, see, feel or have the strength or dexterity to cut their nails.<sup>12</sup> The result is that the nails go unmanaged and provide a significant and often overlooked area of risk for lower extremity infection and limb loss.<sup>11,12</sup>
- Many diabetic patients have loss of protective sensation that will result in their inability to feel any of the warning signs of infection in their feet.
- Advanced peripheral neuropathy will also lead to motor neuropathy resulting in an imbalance of the stabilizing muscles of the foot causing deformity such as digital overlap and hammertoes, as significant precursors to fungal infections and ulcerations.<sup>12,15,16</sup>



**Figure 1.** Toe onychomycosis. Mild - distal-lateral subungual



**Figure 2.** Prevalence of toe onychomycosis.<sup>20</sup> Higher Incidence of secondary infections in patients with diabetes

- A simple ingrown nail or a lesser toe deformity that causes the nail to rub into the adjacent toe can easily and too often cause cellulitis or osteomyelitis of the underlying bone.<sup>12</sup>
- Broken skin provides a portal for bacteria and often will start the cascade of diabetic foot complications.<sup>12</sup>
- Early treatment and intervention including diabetic prophylactic foot care education is advisable owing to the progressive nature of fungal infections and the high risk diabetic foot.<sup>12,15,16</sup>
- The long course of treatment for onychomycosis, together with the existing polypharmacy in diabetic patients may lead to monetary challenges and potential side effects.

### Assessment

- Diagnosis of onychomycosis is based on clinical presentation and test results.<sup>1</sup> As there are many disorders that cause nail changes, objective assessment may help clarify the aetiology.
- A practical approach may be to treat topically before testing or while waiting for test results.<sup>1</sup> In clinical practice, treatment is often begun without confirmation of test results. A positive potassium hydroxide microscopic or culture for fungus should be performed before considering using systemic antifungal therapy.<sup>1,8-9,14</sup>
- Fungal infection may also exist with other disorders (e.g. psoriasis / pincer nails) and successful treatment of the fungus will not clear the co-existing disorder.<sup>1</sup>

**The following<sup>1</sup> may be reviewed when a patient presents with onychomycosis:**

- Investigate patient history and what treatment has been utilized.
- Check if there is an incidental finding of onychomycosis.
- Establish the patient's past medical history including age (is the patient elderly), comorbidities such as diabetes, cancer and renal disease.

- Check if the patient is immuno-suppressed or has an inflammatory skin disease such as psoriasis.
- Establish if there is a history of fungus elsewhere, e.g. Tinea pedis.
- Discuss the recreational habits of the patient including their hygiene, environment and athletic wear.
- Establish the patient's foot care maintenance including spa's, self-debridement or pedicures.
- Patient psychological welfare is another important area for assessment, with concerns around how the disease impacts their lifestyle. Ask patients if they are embarrassed about their condition, if the visit to the clinic was their own initiative, and if they are engaged and informed in their health care choices.
- Before considering treatment, it is important to discuss patient expectations of treatment outcomes.<sup>1</sup> The physician must be able to discuss all options and roadblocks that are common with onychomycosis treatment.

### Treatment for Toe Onychomycosis

- A recently published clinical pathway for the prevention and treatment of toe onychomycosis<sup>1</sup> was modified for use by podiatrists and chiropodists and addresses the following steps: aetiology and differential diagnosis, prevention, treatment, evaluation and maintenance strategies (Figure 3).
- Before initiating treatment, patients should be informed about steps they can take to contain the infection and prevent recurrence, such as foot hygiene, use of shower sandals and regular medical pedicures.<sup>1</sup>
- Often patients present with a long history of trying a myriad of home remedies. When recommending treatment, pros and cons of various available options may be discussed.<sup>1</sup>
- Patients may have searched the Internet for information and often have concerns regarding treatments they have read about, such as oral antifungal and hepatic involvement, and various drug-interactions.
- Patients may have heard about laser treatments and may be concerned about cost, side effects, efficacy and the possibility of infection reoccurrence.
- If the patient does not respond to treatment, microscopic or culture confirmation is needed before proceeding to oral therapy.<sup>1,8-9,14</sup>

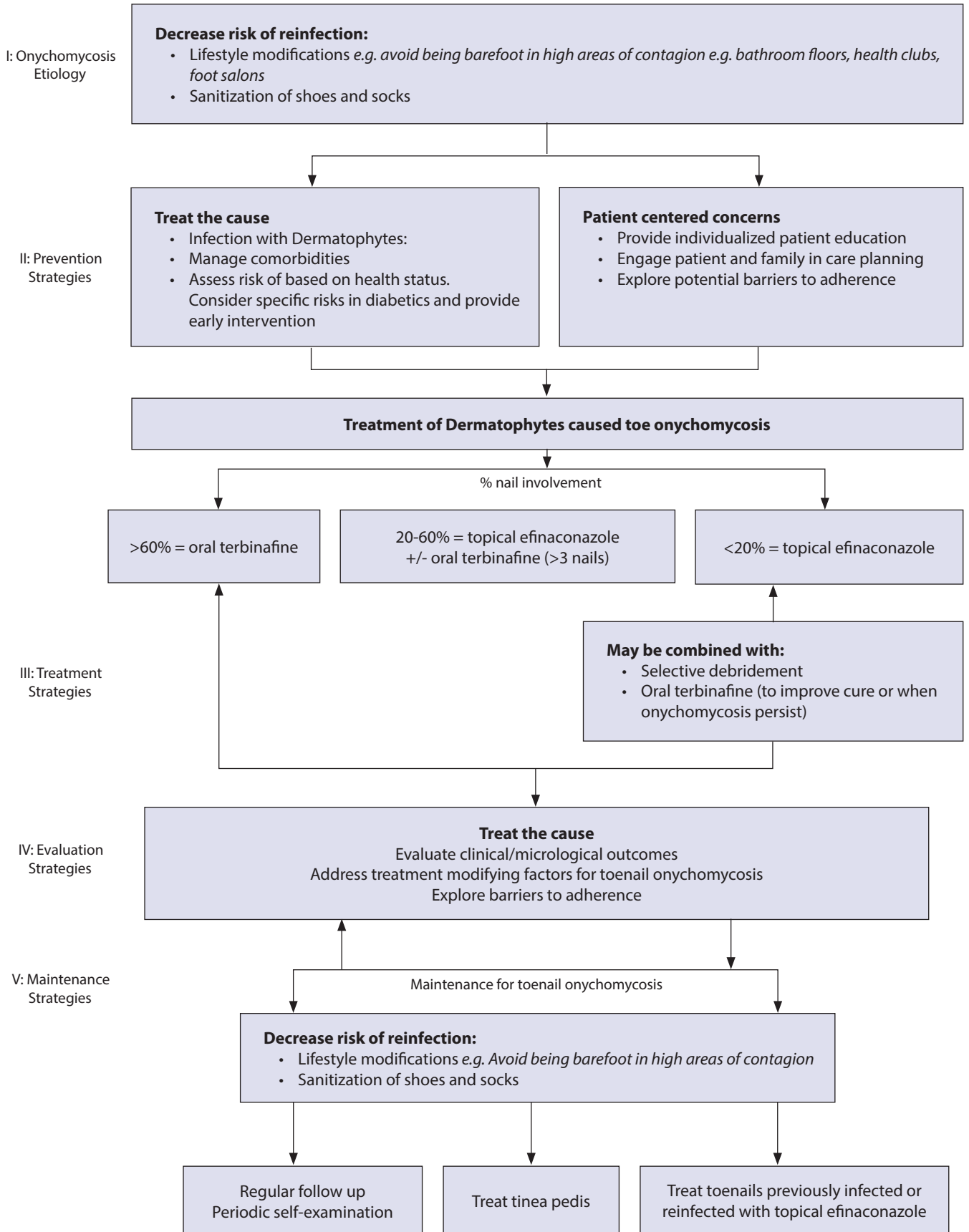
### Systemic Treatment

- Oral treatment is the gold standard for toe onychomycosis with more than 60% nail plate involvement.<sup>8,13</sup> The two options available are Itraconazole (Sporanox (itraconazole), Janssen Pharmaceuticals Inc, Titusville, NJ) and terbinafine (Lamisil (terbinafine HCl), Novartis Pharmaceuticals Corporation, East Hanover, NJ).
- There are issues to be considered when prescribing systemic treatment, such as drug interactions, hepatotoxicity, safety concerns and the need for monitoring.<sup>8</sup>
- Studies of oral treatment that evaluated mycologic cure at week 48, defined as negative KOH and negative culture,<sup>8</sup> showed terbinafine HCl to be more effective, with a 70% healing rate versus 54% with itraconazole. For complete cure rates, terbinafine was equally more effective, with 38% complete cure versus 14% for itraconazole.<sup>8</sup>

### Topical Treatment

- Topical nail preparations are indicated for distal subungual and superficial white patterns of nail onychomycosis.<sup>1,10</sup>
- Some topical antifungal agents act as a lacquer applied to the nail surface (e.g. Penlac lacquer with the antifungal ciclopirox).<sup>8,19</sup> This specific topical treatment should be combined with selective debridement of the nail, to enable penetration.<sup>19</sup>
- Newer topical or transungual agents have the ability to penetrate nail keratin.<sup>10</sup>
- The non-lacquer transungual treatment containing efinaconazole 10% solution has demonstrated clinical effectiveness when applied as monotherapy in patients with mild-to-moderate toe onychomycosis.<sup>10</sup> The primary efficacy endpoints (complete

# Toenail Onychomycosis



**Figure 3.** Pathway to the prevention and treatment of toe onychomycosis

clinical cure and mycologic cure) were significantly greater than vehicle at week 52 ( $p < 0.001$ ) and clinical improvement continued after treatment was stopped (week 48).<sup>10</sup>

### Laser Treatment

- Laser may be used for the treatment of onychomycosis with an emphasis on clinical improvement of the nail.<sup>17,18</sup>
- Protocols include debridement of the nail, followed by laser therapy 5-7 times, with more passes (not increasing joules) to disrupt fungus sepsis.<sup>17,18</sup>
- Treatment with laser may take 3-4 months or more.<sup>17,18</sup>
- The efficacy of laser therapy is a subject of debate and currently research has not demonstrated sustained efficacy.<sup>18</sup>
- It has become common practice to adopt a universal foot care approach for the utilization of laser therapy, which includes addressing concomitant Tinea pedis infections, hygiene, shoe gear and sock changes, and habit changes including awareness of environmental factors such as gym or locker room floor contamination.
- The patient must be educated about foot care due to the high chance of recurrence and must not rely solely on one treatment modality.

### Conclusion

- A large population of onychomycosis patients are seen in podiatrist and chiropodists offices,<sup>1,15</sup> and the incidence is increasing particularly among young, elderly and diabetic patients.<sup>2,4</sup>
- Diabetic foot ulcer guidelines identify onychomycosis as a high-risk factor for complications, even amputation.<sup>12</sup> Early diabetic foot examination should include screening for onychomycosis.
- A diabetic foot exam will include a dermatological evaluation, vascular assessment, neurological evaluation and biomechanical review<sup>11,12,15,16</sup> to identify the associated risk factors and enable accurate categorization of the patient's condition (e.g. low, medium or high-risk status).<sup>12</sup>
- Even though foot examination in diabetic patients is common practice, onychomycosis either goes unnoticed or is left untreated and remains unresolved in many patients. It is imperative that patients be engaged in diabetic foot education.
- The information obtained enables the physician to develop an effective plan for prevention and treatment.
- The goal of management is to educate the patient, assess risk factors and manage those risks in a prophylactic manner.<sup>12,15</sup>
- Health care providers must be aware of patient barriers regarding treatment and foot care. To that end, it is quite common to include the family or caregivers in conversations concerning risk factors and foot care for in patients with diabetes.
- Efinaconazole solution is effective in patients that have mild to moderate onychomycosis where the nail is less than 60% involved and less than 3 nails in total are involved. Moreover, it is a good option when systemic onychomycosis treatment is contraindicated.<sup>1</sup>
- Transungual onychomycosis treatment has benefits over systemic treatment as both patients and clinicians prefer to avoid systemic side effects and the need for monitoring.<sup>17</sup>
- When using a topical agent, the properties of nail plate – thickness and the relative compact structure of the nail – must be addressed.
- A limitation associated with using topical lacquer treatments is the necessity of frequent nail debridement to enable treatment penetration.<sup>19</sup>
- Efinaconazole 10% solution is a non-lacquer alcohol-based formulation that has a low molecular weight and binds with keratin.<sup>10</sup> The product is easy to administer, with a plastic squeeze bottle with a flow-through brush used for application.<sup>1,10</sup>
- Although the transungual efinaconazole 10% solution does not require debridement to be effective in individuals with onychomycosis, high-risk diabetic foot patients do require assessment, daily observation and possibly nail debridement.<sup>12</sup>
- Treatment that can be topically applied should be offered.<sup>12,15</sup>

- When onychomycosis is treated early with efinaconazole solution, complications may be avoided, including the serious and costly outcome of limb salvage.<sup>10,12</sup>
- It is imperative that prevention measures be taken to reduce the risk of recurrence. These measures include, but are not limited to lifestyle modifications (avoid being barefoot in high areas of contagion), sanitization of shoes and socks, regular follow up and periodic foot exams, treat tinea pedis and treat toenails previously infected or reinfected with topical medication.

### References

1. Gupta AK, Sibbald RG, Andriessen A, Belley R, Boroditsky A, Botros M, Chelin R, Gulliver W, Keast D, Raman M. Toenail Onychomycosis—A Canadian Approach With a New Transungual Treatment: Development of a Clinical Pathway. *J Cutan Med Surg*. Sep-Oct; 19(5): 440-9, 2015.
2. Gupta AK, Gupta MA, Summerbell RC, Cooper EA, Konnikov N, Albreksi D. The epidemiology of onychomycosis: possible roles of smoking and peripheral arterial disease. *J Eur Acad Dermatol Venerol* 1: 466-469, 2000
3. Vender RB, Lynde CW, Poulin Y. Prevalence and epidemiology of onychomycosis. *Cutan Med Surg* 10 (Supp 2): 528-33, 2006.
4. Gupta AK, Jain HC, Lynde CW, et al. Prevalence and epidemiology of unsuspected onychomycosis in patients visiting dermatologists' offices in Ontario, Canada—a multicenter survey of 2001 patients. *Int J Dermatol* 36 (10): 783-7, 1997.
5. Rich P: Onychomycosis and tinea pedis in patients with diabetes. *J Am Acad Dermatol* 43: S130-4, 2000.
6. Baran et al., 33% of onychomycosis patients also have tinea pedis and this has implications on recurrence rates. *Arch derm* 142: 1279-84, 2006.
7. Reich A, Szepietowski JC. Health-related quality of life in patients with nail disorders. *Am J Clin Dermatol*. 12: 313-320, 2011.
8. Lecha M, Effendy I, Feuilhade de Chauvin M, Di Chiacchio N, Baran R. Treatment options—development of consensus guidelines. *J Eur Acad Dermatol Venerol*. 19 (Suppl): 25-33, 2005.
9. Tosti A, Hay R, Arenas-Guzman R. Patients at risk of onychomycosis—risk factor identification and active prevention. *J Eur Acad Dermatol Venerol*. 19 (Suppl): 13-16, 2005.
10. Elewski B, Rich P, Pollak R, Pariser DM, Watanabe S, Senda H, Ieda C, Smith K, Pillai R, Ramakrishna T, Olin JT. Efinaconazole 10% solution in the treatment of toenail onychomycosis: Two phase III multicenter, randomized, double-blind studies. *J Am Acad Dermatol* 68 (4): 600-8, 2013.
11. Joseph W., Onychomycosis in the Patient with Diabetes, Diabetic Microvascular Complications today, 25-27, 2005.
12. Botros M, et al. Best practice recommendations for the prevention, diagnosis and treatment of diabetic foot ulcers: Update 2010. *Wound Care Canada* 8 (4): 6-40, 2010
13. Ginter-Hanselmayer G, Weger W, Smoile J. Onychomycosis: a new emerging infectious disease in childhood and adolescents. Report on treatment experience with terbinafine and itraconazole in 36 patients. *J Eur Acad Dermatol Venerol* 22 (4): 470-475, 2008..
14. Shemer A, Davidovici B, Grunwaldk MH, Trau H, Amichal B. New criteria for the laboratory diagnosis of nondermatophyte moulds in onychomycosis. *Br J Dermatol* 160 (1): 37-39, 2009.
15. Mayser P, Freund V, Budihardja D. Toenail onychomycosis in diabetic patients: issues and management. *Am J Clin Dermatol* 10 (4): 211-220, 2009.
16. Bristow IR, Spruce MC. Fungal foot infection, cellulitis and diabetes: a review. *Diabet Med* 26 (5): 548-51, 2009.
17. Harris DM, McDowell B, Strisower J. Laser treatment for toenail fungus. *Proc SPIE* 7161A: 1-7, 2009.
18. Bornstein E. A review of current research in light-based technologies for the treatment of podiatric infectious disease states. *JAPMA* 99 (4): 348-352, 2009.
19. Shemer A, Nathansohn N, Trau H, et al. Ciclopirox nail lacquer for the treatment of onychomycosis: an open non-comparative study. *J Dermatol* 37(2): 137-139, 2010.
20. Joseph W. Onychomycosis in the Patient with Diabetes, Diabetic Microvascular Complications today, 25-27, 2005.

SIGN UP FOR YOUR FREE SUBSCRIPTION

# Skin Therapy Letter<sup>®</sup>

Family Practice Edition

Editor-in-Chief: Dr. Charles Lynde

Go online to [www.SkinTherapyLetter.com](http://www.SkinTherapyLetter.com) and sign up today!

To get more information, Canadian medical professionals and consumers can access all of our sites from [www.SkinCareGuide.ca](http://www.SkinCareGuide.ca) or go directly to:

*Patient sites:*

<a href="http://AcneGuide.ca">AcneGuide.ca</a>	<a href="http://ActinicKeratosi.ca">ActinicKeratosi.ca</a>	<a href="http://BotoxFacts.ca">BotoxFacts.ca</a>	<a href="http://ColdSores.ca">ColdSores.ca</a>
<a href="http://CosmeticProcedureGuide.ca">CosmeticProcedureGuide.ca</a>	<a href="http://DermatologyCare.ca">DermatologyCare.ca</a>	<a href="http://EczemaGuide.ca">EczemaGuide.ca</a>	<a href="http://FungalGuide.ca">FungalGuide.ca</a>
<a href="http://GenitalWarts.ca">GenitalWarts.ca</a>	<a href="http://HandEczema.ca">HandEczema.ca</a>	<a href="http://HerpesGuide.ca">HerpesGuide.ca</a>	<a href="http://Lice.ca">Lice.ca</a>
<a href="http://MildCleanser.ca">MildCleanser.ca</a>	<a href="http://MohsSurgery.ca">MohsSurgery.ca</a>	<a href="http://PsoriasisGuide.ca">PsoriasisGuide.ca</a>	<a href="http://PsoriaticArthritisGuide.ca">PsoriaticArthritisGuide.ca</a>
<a href="http://RosaceaGuide.ca">RosaceaGuide.ca</a>	<a href="http://SkinCancerGuide.ca">SkinCancerGuide.ca</a>	<a href="http://SkinCoverup.com">SkinCoverup.com</a>	<a href="http://Sweating.ca">Sweating.ca</a>
<a href="http://UnwantedFacialHair.ca">UnwantedFacialHair.ca</a>			

*Medical professional sites:*

<a href="http://Dermatologists.ca">Dermatologists.ca</a>	<a href="http://PASItraining.com">PASItraining.com</a>	<a href="http://SkinPharmacies.ca">SkinPharmacies.ca</a>	<a href="http://SkinTherapyLetter.com">SkinTherapyLetter.com</a>
--	--	--	--

*Social networking sites for patients and health care professionals:*

<a href="http://PsoriasisPatients.com">PsoriasisPatients.com</a>	<a href="http://Youtube.com/SkinExpertsTalk">Youtube.com/SkinExpertsTalk</a>
--	--

We welcome your feedback. Please email us with your comments and topic suggestions to: [info@skintherapyletter.com](mailto:info@skintherapyletter.com)



**Skin Therapy Letter<sup>®</sup>**  
Family Practice App

Available for download on iOS devices

Content & instructions can be found at: <http://itunes.apple.com/us/app/skin-therapy-letter-family/id457954435>

Skin Therapy Letter<sup>®</sup> - Family Practice Edition (ISSN 1911-7671) Copyright 2017 by SkinCareGuide.com Ltd. Skin Therapy Letter<sup>®</sup> - Family Practice Edition is published up to four times annually by SkinCareGuide.com Ltd, 1003 - 1166 Alberni Street, Vancouver, British Columbia, Canada, V6E 3Z3. All rights reserved. Reproduction in whole or in part by any process is strictly forbidden without prior consent of the publisher in writing. While every effort is made to see that no inaccurate or misleading data, opinions or statements appear in the Skin Therapy Letter<sup>®</sup> - Family Practice Edition, the Publishers, and Editorial Board wish to make it clear that the data and opinions appearing in the articles herein are the responsibility of the contributor. Accordingly, the Publishers, the Editorial Committee and their respective employees, officers, and agents accept no liability whatsoever for the consequences of any such inaccurate or misleading data, opinion, or statement. While every effort is made to ensure that drug doses and other quantities are presented accurately, readers are advised that new methods and techniques involving drug usage, and described herein, should be followed only in conjunction with the drug manufacturer's own published literature.